

A Rare Presentation of Midgut Malrotation as an Acute Mesenteric Ischaemia in an Adult with Bilateral Renal Calculi and Bilateral Renal Cortical Cysts.

Kannan Kanagaraj; Prabakaran Maduraimuthu; Siddhanth.

Department of radiology, Sree Balaji Medical College and hospital, Chennai, Tamil Nadu.

ABSTRACT:- Midgut malrotation refers to twisting of the entire midgut about the axis of the superior mesenteric artery.

Malrotation occurs in approximately 1 in 500 live births. However, the true incidence of malrotation is unknown, since many asymptomatic patients fail to present. □ Approximately 90% of patients with malrotation are diagnosed within the first year of life, 80% of whom are diagnosed within the first month of life. Thereafter, it can present in adults of any age. In our study 68 year old male presented with pain abdomen.

CECT demonstrated malrotation and acute mesenteric ischaemia. Superior mesenteric vein thrombosis is the cause for acute mesenteric ischaemia which is account for 5%–10%. Mesenteric ischaemia is divided into acute and chronic based upon the rapidity and the degree to which the blood flow is compromised. The purpose of this article is to document in understanding of malrotation and acute bowel ischemia and to define the role of CECT in the diagnosis of Superior mesenteric venous thrombosis.

The authors reviewed this case and diagnosed by computed tomography and they confirmed by surgery and clinical follow-up.

Keywords: mal rotation, Acute mesenteric ischemia, smv thrombosis computed tomography,

I. Introduction

Malrotation results not only in the malposition of the bowel but also in the malfixation of the mesentery.

The normal arrangement of Superior mesenteric vein and Superior mesenteric artery in the upper mesenteric root is the result of complete 270 degree counterclockwise rotation of the midgut in the developing embryo. Midgut malrotation occurs when midgut undergoes less than the normal 270 degree of counter clock wise rotation. In our study the Superior mesenteric vein lay on the left ventral aspect of the

Superior mesenteric artery instead of on the right ventral aspect. This aspect suggests a failure of the Superior mesenteric vein to rotate around the Superior mesenteric artery by 90 degree of its normal counterclockwise travel. Occlusions of mesenteric may be primary or secondary and may be found proximally or distally. Isolated proximal mesenteric venous thromboses, however, usually do not lead to severe bowel ischemia because of the extended collateral network between mesenteric and systemic veins.

There are three stages of acute bowel ischemia. The first stage, which is characterized by mucosal necrosis and mucosal erosion or hemorrhage, is reversible.

In stage II, the damage extends to submucosal and muscular layers. Stages I and II are poorly identified on CT. Mucosal enhancement and wall thickening can be detected, but those findings are usually mild and nonspecific. In stage III, which represents transmural bowel wall necrosis, the CT findings are more reliable and specific, and include abnormal or absent wall enhancement, mesenteric stranding and ascites.

We report the case of a malrotation with acute mesenteric ischaemia and occlusive mesenteric venous thrombosis in a 68-year-old patient.

II. Case Presentation

68-year-old man was hospitalized with chief complaints of pain abdomen, vomiting, decreased appetite and fever.

During hospitalization, the patient complains of generalized abdominal pain was diffuse and continuous more pronounced after taking meal. Vomiting is projectile in nature and contains food particles. On physical examination, patient was conscious had stable vital signs and 38 °C febrile.

Abdominal examination revealed there is generalized

Abdominal pain and no evidence of organomegaly or dilated veins. The rest of the physical examination was unremarkable.

III. Laboratory Studies

Total bilirubin 2.3mg/dl Direct bilirubin
1.7mg/dl Albumin 2.1gm/dl Bld urea
89mgm Bld sugar 175mgm/dl

The patient underwent surgery with per Operative finding of small bowel gangrene 10 cm away from ileocaecal junction and malrotation of the small bowel. There is evidence of ascites and no perforation. The postoperative period was uneventful with favorable clinical and biological parameters.

CT Technique

CT images are obtained from the dome of the liver to the level of the perineum to cover the entire course of the intestine. The role of contrast-enhanced CT is to identify thrombi in the mesenteric arteries and veins, abnormal enhancement of the bowel wall, and the presence of embolism or infarction of other organs. For contrast-enhanced CT, 100–150 ML of iodinated contrast material is administered at a rate of 2–5 mL/s, and scanning starts with delay times of 30 and 60 seconds for dual acquisition and 40–60 seconds for single acquisition.

The authors retrospectively reviewed case of midgut malrotation and mesenteric ischemia, diagnosed by CT and confirmed by surgery.

IV. Cect Findings

Long segment thrombosis involving the SMV and extrahepatic portal vein. Thrombus also noted within proximal tributaries of SMV. It is seen distending and completely filling the SMV in some segments.

Long segment circumferential bowel wall thickening about 40cm involving the small bowel loops (proximal/mid ileal loops) due to ischaemic causes of venous thrombosis. Bowel wall thickness 7.9mm with mild mucosal enhancement. Some of the tributaries of SMV close to the bowel show normal enhancement. Significant dilatation of small bowel loops involving the jejunal and proximal ileal loops. Malrotation of bowel loops seen with duodenum and DJ flexure to the right of midline.

Entire colon is seen to the left of midline. Altered SMA and SMV axis is seen which denotes malrotation. Smaller hypodense filling defects noted in the intrahepatic portal vein Right portal vein – thrombus.

Large wedge shaped hypodensity noted involving Right lobe liver- altered parenchymal perfusion due to portal vein thrombosis. Moderate acutis. Bilateral renal calculi. Bilateral renal cortical cysts.

V. DISCUSSION

The diagnosis of midgut malrotation and acute Mesenteric ischaemia remains a clinical challenge.

Altered SMA and SMV axis denotes Midgut malrotation
Which causes inadequate blood flow through the mesenteric vessels, resulting in ischemia and eventual gangrene of the bowel wall?

Acute mesenteric ischemia can be caused by various conditions such as arterial occlusion, venous occlusion, strangulating obstruction, and hypoperfusion associated with nonocclusive vascular disease. Though several modalities such as ultra sonogram,

Duplex Doppler of SMA and SMV, barium studies and angiography are available to diagnose malrotation, acute mesenteric ischaemia, ascites and bilateral renal problem, Contrast-enhanced CT is an important diagnostic tool, including 3D and multiplanar reconstructions. In our study the most prevalent CT findings were related to bowel wall, including thickening, distension and hyper enhancement.

Thickening of the bowel wall is the most frequent CT finding pertaining to acute mesenteric ischaemia. There is evidence of Thrombus in intra hepatic portal vein and right portal vein. Right lobe liver also shows large wedge shaped hypodensity due to altered parenchyma perfusion due to portal vein thrombosis.

CT performance in diagnosing strangulation is reported as 83–100% insensitivity, 61–93% in specificity, 72–88% in positive predictive value, and 93–100% in negative predictive value.

VI. Conclusion

An accurate and early diagnosis is essential for the appropriate and successful treatment of patients with acute mesenteric ischemia, malrotation and superior mesenteric vein thrombosis to improve their prognoses. For a correct diagnosis, a technically appropriate CT examination and proper interpretation of images are mandatory. Because acute mesenteric is chemia can be caused by various conditions, the CT findings vary widely, depending on the cause and underlying pathophysiology and the presence of associated complications. Recognition of the characteristic CT appearances and variations of each cause may help in the accurate interpretation of CT in the diagnosis of mesenteric ischemia.

References

- [1]. Taourel PG, Deneuille M, Pradel JA, et al. Acute mesenteric ischemia: diagnosis with contrast-enhanced CT. *Radiology* 1996; 199:632-636. Link
- [2]. Horton KM, Fishman EK. Volume-rendered 3D CT of the mesenteric vasculature: normal anatomy, anatomic variants, and pathologic conditions. *RadioGraphics*. 2002;22:161
- [3]. Rha SE, Ha HK, Lee SH, et al. CT and MR imaging findings of bowel ischemia from various primary causes. *RadioGraphics*. 2000;20:29.
- [4]. Kim JY, Ha HK, Byun JY, et al. Intestinal infarction secondary to mesenteric venous thrombosis: CT-pathologic correlation. *J Comput Assist Tomogr* 1993; 17:382-385. CrossRef, Medline

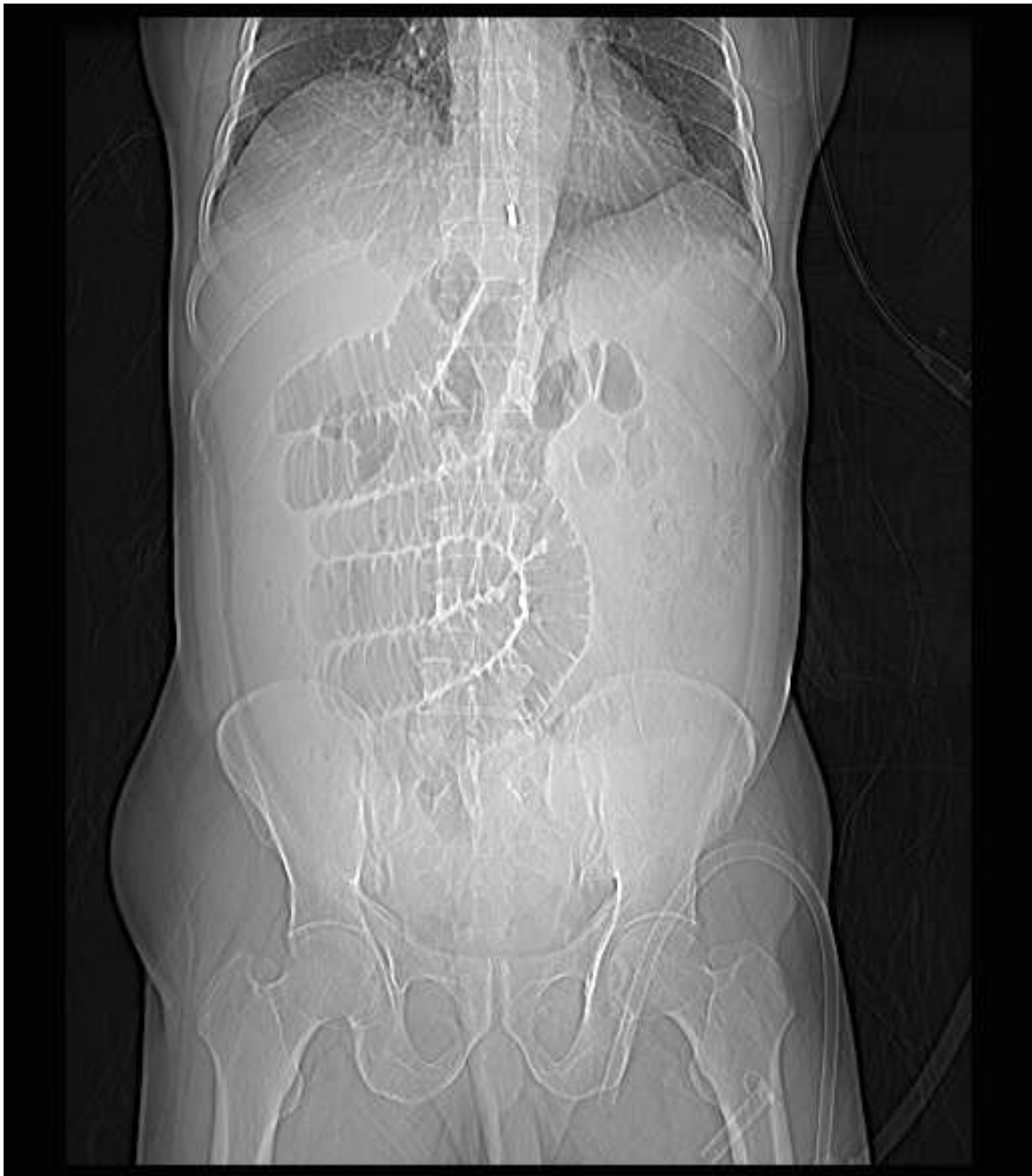


Figure1. Dilated Small bowel loops are on RT side and over the spine. - MALROTATION

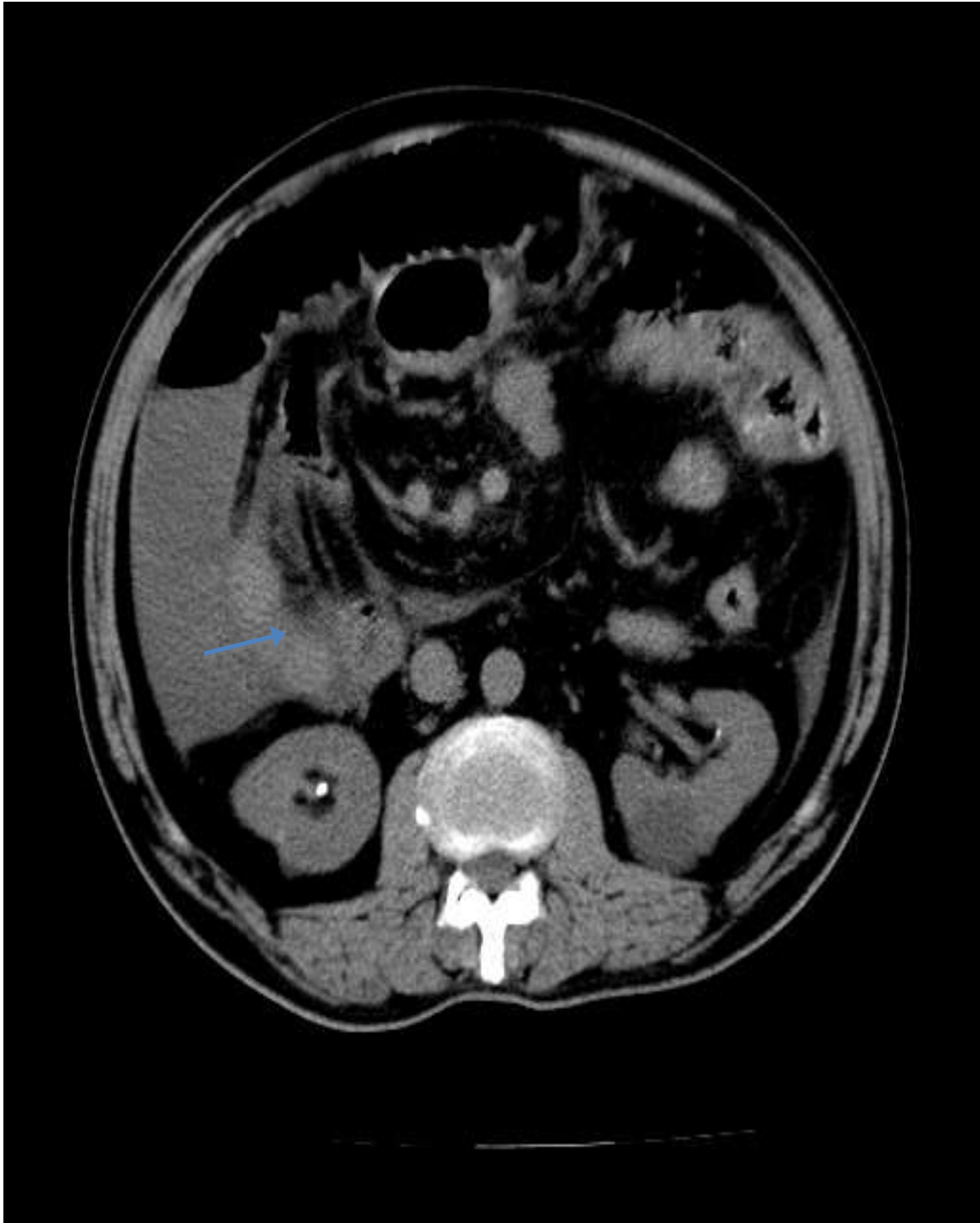


Figure 2. Non Contrast axial CT shows Rt renal calculus - arrow

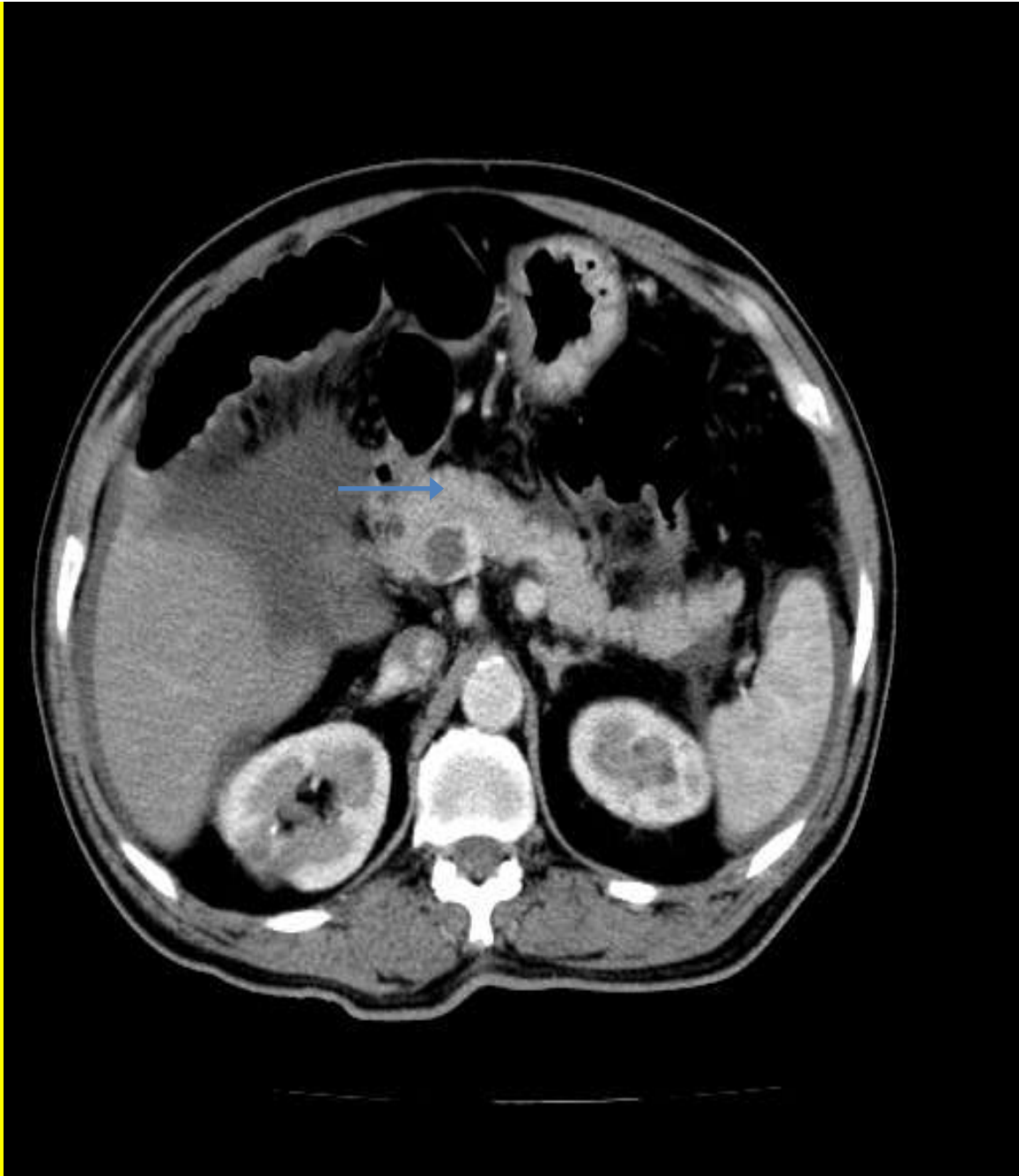


Figure 3. CECT axial section demonstrates superior mesenteric vein thrombosis- arrow

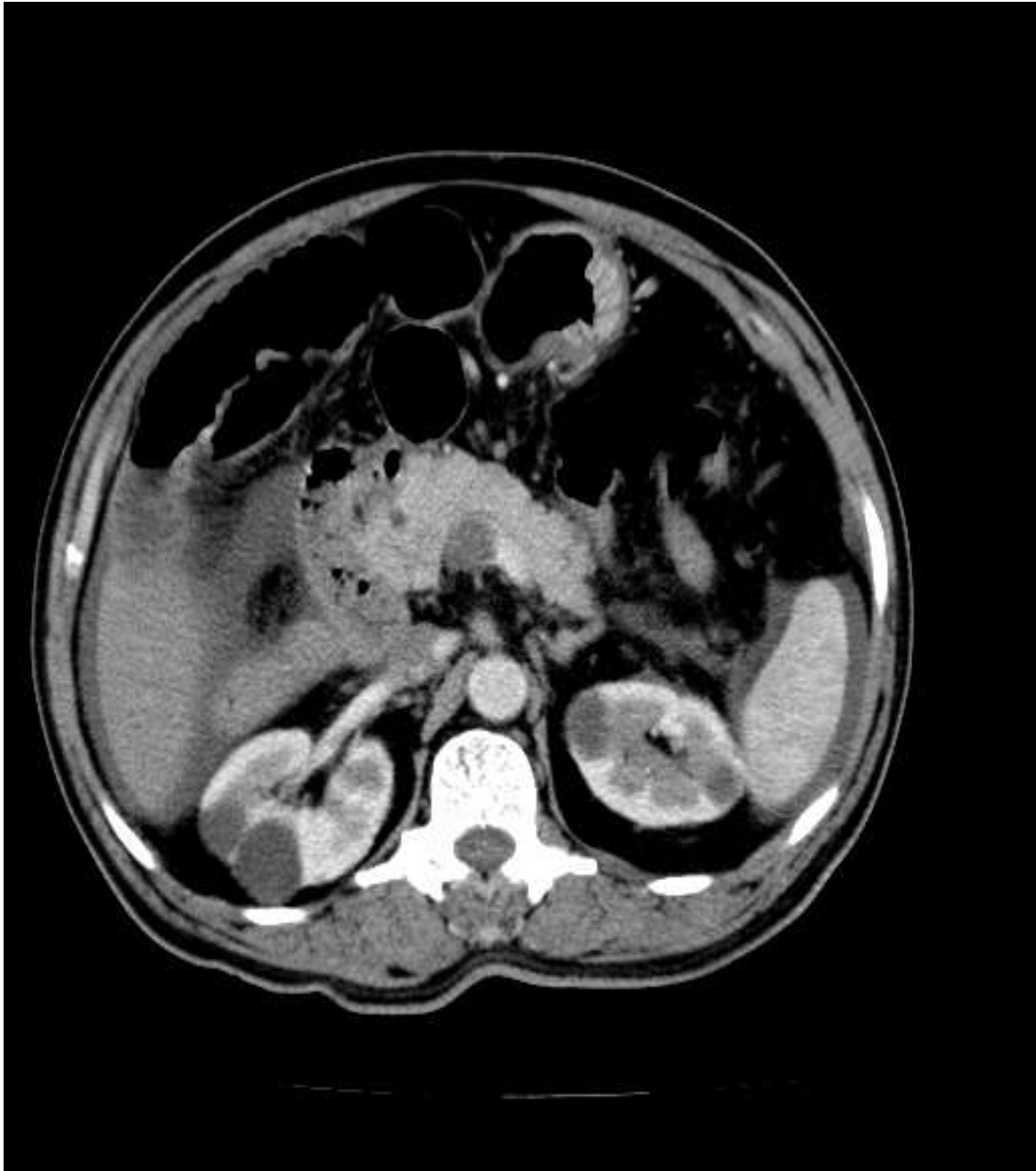


Figure 4. CECT Axial section shows bilateral renal cortical cysts.

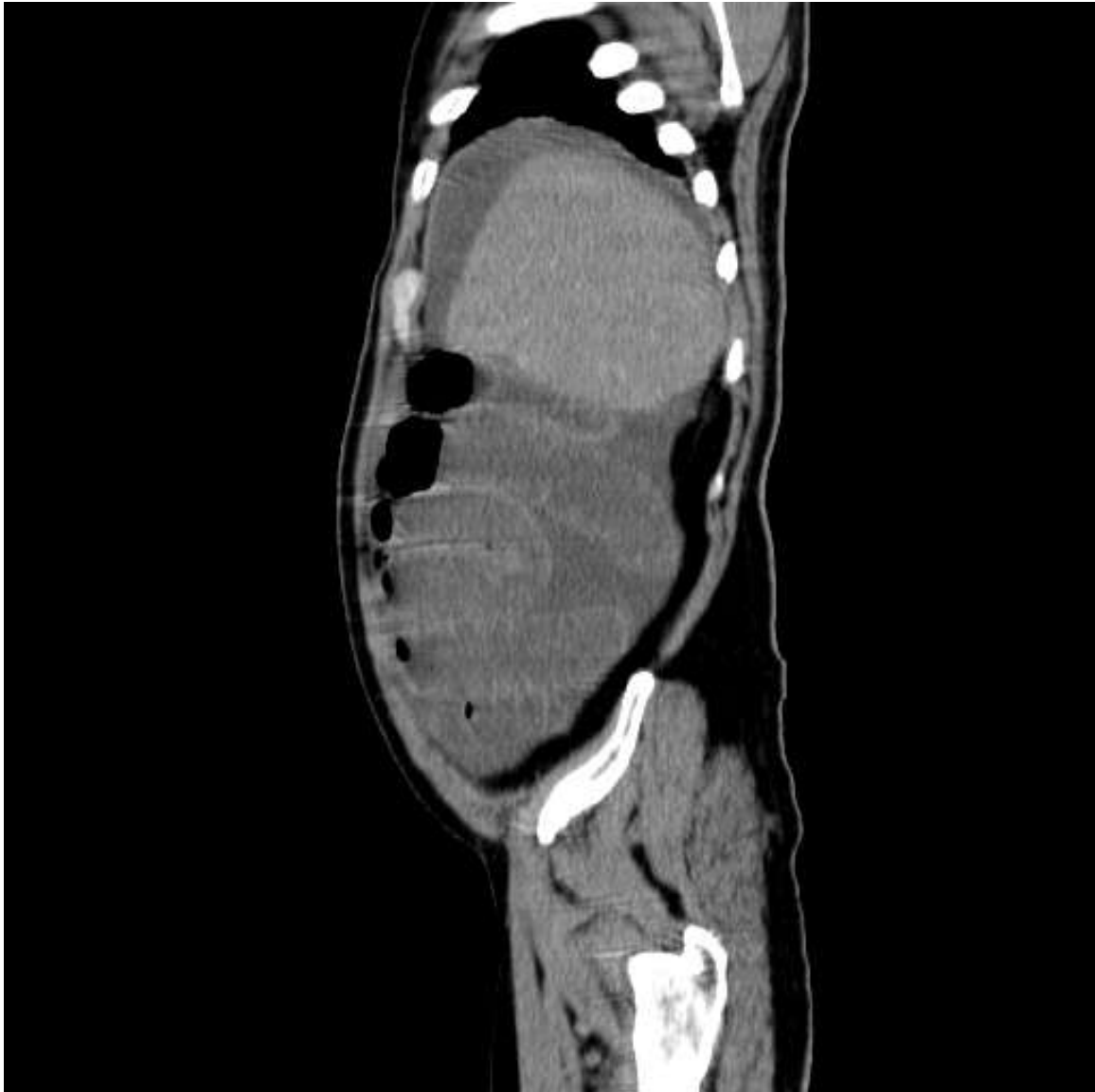

Figure 5.plain CT Sagittal. Ischaemic dilated small bowel loops and ascites.

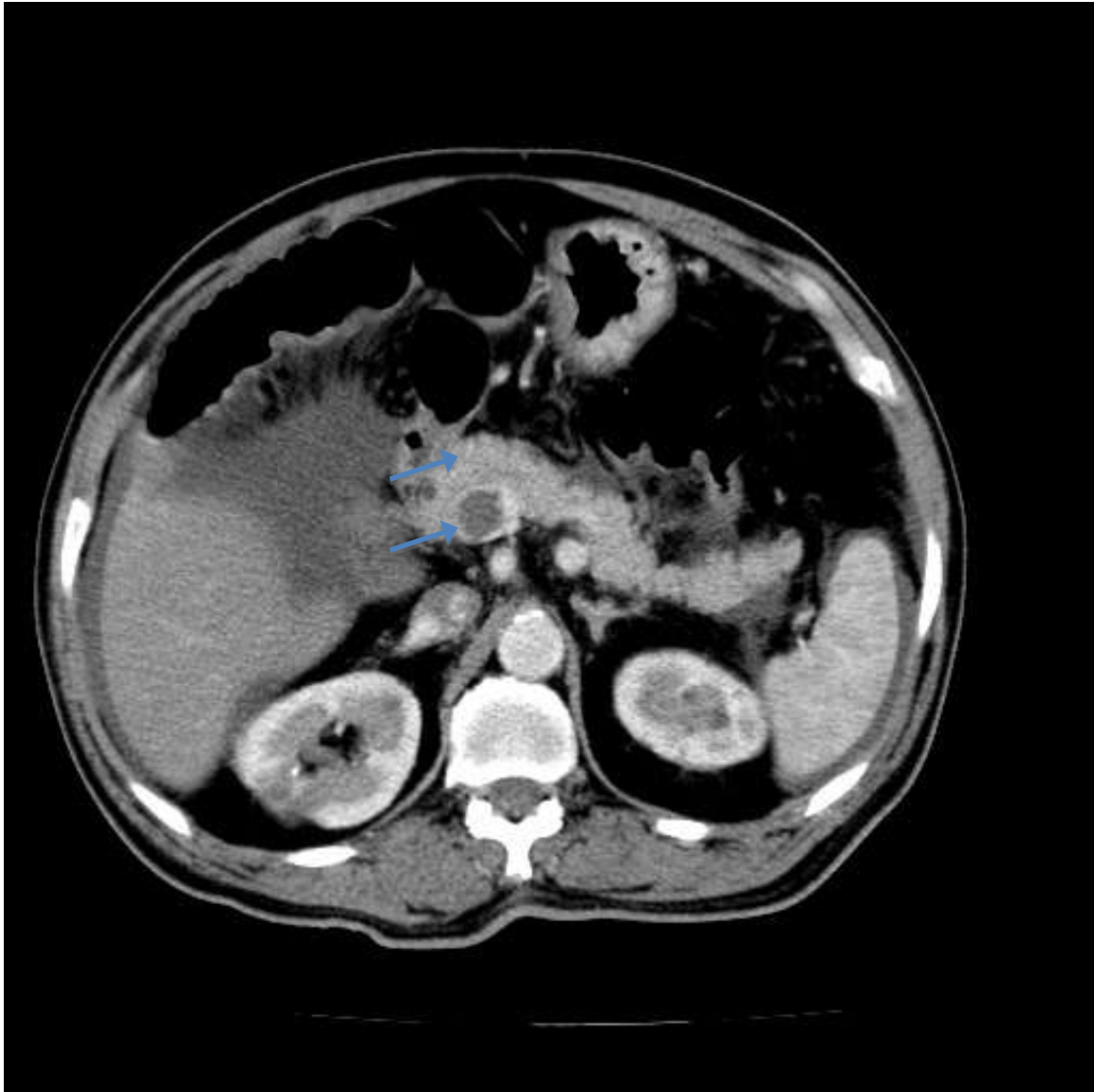


Figure 6. Axial CECT - superior mesenteric artery and superior mesenteric vein axis are altered- malrotation. SMV- long arrow. SMA- small arrow